



PATIENT

Raven Chavez

PRESENTING CLINICAL SIGNS

History: Screening for ARVC - Sibling died.

SPECIES

Canine

BREED

Boxer

SEX

Female Spayed

AGE

8 years

WEIGHT

58.6lbs

ELECTROCARDIOGRAPHIC FINDINGS *Note: Single lead ECGs are evaluated as a rhythm strip.

Morphology/MEA cannot be definitively commented on.

A single lead ECG is available; 50mm/s, 20mm/mV, 22 second duration. Dramatic motion artifact.

The average heart rate is 90bpm with what appears to be respiratory variation. The rhythm is sinus in origin, with a p for every QRS complex and vice versa. The P and QRS morphologies are positive. Isolated monomorphic VPCs are identified; three in a 20 second tracing. No

supraventricular premature beats, pauses or other dysrhythmias observed.

ECG diagnosis: Respiratory sinus arrhythmia with isolated VPCs.

ECHOCARDIOGRAM FINDINGS

2D, m-mode, color flow and doppler imaging is available. The mitral valve appears normal in form and function, with no obvious prolapse into the left atrial lumen. No MR seen. Normal left atrial dimension. Normal LV diameter with adequate myocardial function. Normal LV wall thickness.

The tricuspid valve appears normal in form and function with no TR. No overt evidence of pulmonary arterial hypertension or right heart compensation, however right heart is prominent.

No tricuspid regurgitation. The aortic valve is normal in morphology and mobility. No subvalvular ridge present, mildly increased velocity. No aortic insufficiency. Normal pulmonic valve with no pulmonic insufficiency seen. No pericardial or pleural effusion noted. No obvious cardiac tumors. Irregular rhythm noted throughout the examination.

CARDIAC CHART

INTERPRETED BY

Maggie Machen Lamy,
DVM, DACVIM
(Cardiology)

IMAGING PERFORMED BY

Dana Alterman,
RDCS, LVT

HOSPITAL NAME

Eubank Animal Clinic

REFERRING VET

Dr. Russman

INVOICE

23742

DATE

4/18/22

CANINE CARDIAC PARAMETERS	MR VMAX (m/s)	TR VMAX (m/s)	LA/AO (Boon method)	LA/AO (Heart Base; Swe)	FS (%)	EF (%)	EPSS (cm)
NORMAL PARAMETER	4.5-5.5	<2.7	1.3	<1.6	28-40	40-100	<0.6
PATIENT	NA	NA	NM	1.3	40	74	NM
CANINE CARDIAC PARAMETERS	HR (BPM)	AV VMAX (m/s)	PV MAX (m/s)	BODY WEIGHT (kg)	LA 2D short axis Base view (cm)	LVIDd Avg; 2D and m-mode short axis (cm)	LVIDs Avg; 2D and m-mode short axis (cm)
NORMAL PARAMETER	50-100	0.7-1.7	0.7-1.6	BELOW	BELOW	BELOW	BELOW
PATIENT	NM	1.1	1.2	26.6	2.5	4.5	2.7
*Normal chamber parameters expressed as a mean value (SD)				3	1.27 (5.3)	2.46 (2.46)	1.36 (5.5)
BODY WEIGHT DEPENDENT PARAMETERS				5	1.40 (4.5)	2.74 (5.2)	1.60 (4.7)
<i>*Note: All measurements based upon multi-modal images and methods. An average value is reported.</i>				10	1.50 (3.8)	3.27 (3.5)	2.06 (3.1)
				15	1.83 (2.0)	3.71 (2.4)	2.43 (2.1)
				20	2.02 (1.9)	4.14 (2.2)	2.80 (2.0)
				25	2.18 (2.4)	4.48 (2.9)	3.10 (2.5)
				30	2.33 (3.3)	4.83 (3.9)	3.39 (3.4)
				35	2.48 (4.3)	5.17 (5.0)	3.69 (4.5)
				40	2.62 (5.2)	5.48 (6.1)	3.96 (5.4)
				50	2.88 (7.1)	6.07 (8.3)	4.46 (7.4)

Adapted from June Boon, Veterinary Echocardiography, 1998
Rishniw M and Hollis NE, J Vet Intern Med 2000; 14:429-435
Hansson et al, Vet Rad and Ultrasound 2002
Bonagura et al. Echocardiography: principles of interpretation, Vet Clin North Am 15:1177, 1995



PATIENT	<u>INTERPRETATION OF THE FINDINGS & FURTHER RECOMMENDATIONS</u>
Raven Chavez	The cardiac structure and function are essentially normal in this patient. There is mild right heart prominence in some views, however this is angle dependent and may be a normal variant. The left heart dimensions are normal, and the systolic function considered adequate for a large breed dog. No additional issues are identified.
SPECIES	
Canine	
BREED	
Boxer	The ECG does confirm ventricular premature contractions in this patient. VPCs are generated from abnormal conductive or fibrotic tissue in the ventricles of the heart muscle, and even frequent single VPCs will often cause no clinical signs in dogs. When sustained however, ventricular tachycardia can lead to symptoms such as lethargy and collapse.
SEX	VPCs are a very non-specific finding. They can be primary in origin (such as ARVC), be secondary to significant cardiac disease (not present in this study) or be extra-cardiac in origin, i.e., due to pain, stress, inflammation, cancer, GI disease, DIC/sepsis, etc. In a senior Boxer, there is high suspicion for ARVC (the most common age of onset 6-8yo, often asymptomatic). ARVC can occur with or without systolic dysfunction and structural issues, however this should be monitored going forward for any progressive issues. It is always reasonable to rule out other differentials for VPCs (AUS, tick titers, troponin, etc.) however suspicion is low given the signalment of the patient. Unfortunately, there is always an elevated risk for collapse and sudden death in any arrhythmic patient, and even on medications this risk unfortunately still persists. ARVC carries a HIGHLY variable prognosis, with some dogs able to remain asymptomatic for extended periods of time, and others developing exercise intolerance, syncopal episode, and refractory arrhythmias/sudden death imminently.
Female Spayed	
AGE	
8 years	
WEIGHT	
58.6lbs	
INTERPRETED BY	Based strictly upon the amount of arrhythmia present on the available ECG in this asymptomatic dog, anti-arrhythmic therapy is not clearly indicated. This is based upon only single beats on a very brief ECG. An extended time 6 lead ECG and/or holter monitor is highly recommended as the next step to fully understand the amount of arrhythmia present within 24 hours. If this is declined, given a family history of sudden death, Sotalol can be initiated as an alternative approach. Discussion with the owner is advised
Maggie Machen Lamy, DVM, DACVIM (Cardiology)	
IMAGING PERFORMED BY	Fish oil supplementation is recommended for dogs with arrhythmias (1000mg of omega 3 and 6 once to twice daily as tolerated).
Dana Alterman, RDMS, LVT	
HOSPITAL NAME	Anesthetic risk is considered moderate. Avoid ketamine, telazol, Dexdomitor (or other alpha-2 agonists) and acepromazine. Recommend having lidocaine CRI available for use in the event of worsening ventricular arrhythmias under anesthesia (CRI 50–75mcg/kg/min). Monitor at home for collapse, exercise intolerance, and/or lethargy. Anesthesia is not recommended until good arrhythmic control is achieved. Lifelong mild to moderate activity restriction is advised.
Eubank Animal Clinic	
REFERRING VET	<u>PLAN</u>
Dr. Russman	Consider a holter monitor. If declined or not possible, institute sotalol 80mg tablets, give ½ tab PO q12h. Recheck ECG in 1-2 weeks to assess response (goal is significant reduction in ectopy without a significant change in underlying sinus rate).
INVOICE	Recheck ECG and echocardiogram is recommended in 6 months to determine progression/control, sooner if any development of associated clinical signs.
23742	
DATE	
4/18/22	



PATIENT

Raven Chavez

SPECIES

Canine

BREED

Boxer

SEX

Female Spayed

AGE

8 years

WEIGHT

58.6lbs

INTERPRETED BY

Maggie Machen Lamy,
DVM, DACVIM
(Cardiology)

IMAGING PERFORMED BY

Dana Alterman,
RDCS, LVT

HOSPITAL NAME

Eubank Animal Clinic

REFERRING VET

Dr. Russman

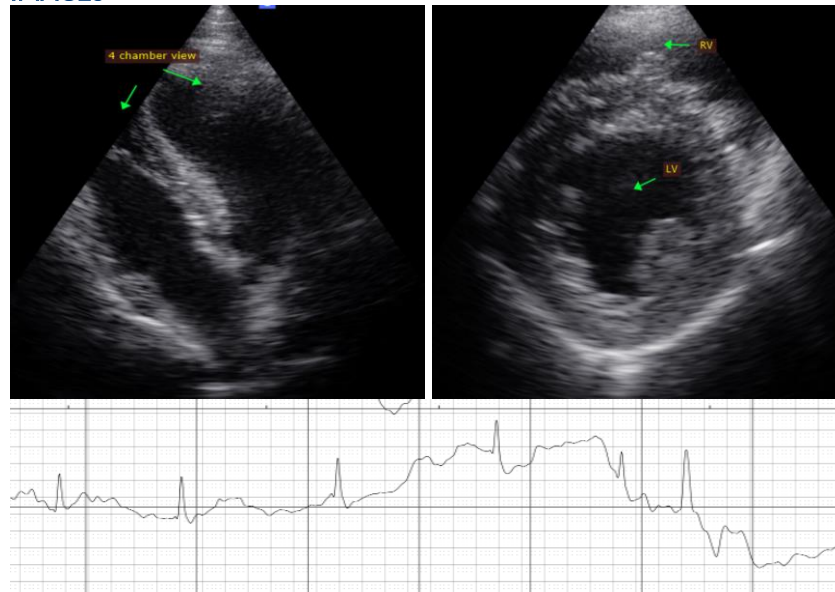
INVOICE

23742

DATE

4/18/22

IMAGES



The information and recommendations provided are based on the images presented by the referring veterinarian. No evaluation can be communicated regarding pathology that was not visible in the image/video clips provided.

Thank you for this referral. This report was generated using transcription software, and minor dictation errors may be present. If the clinical or image interpretation does not parallel your findings or if I can be of any further assistance, please contact me.

Maggie Machen Lamy, DVM
Diplomate of the American College of Veterinary Internal Medicine (Cardiology)
info@sonopath.com